

OUTCOMES OF OUTPATIENT HYSTEROSCOPY IN INFERTILE WOMEN AT THE NATIONAL HOSPITAL OF OBSTETRICS AND GYNECOLOGY

Nguyen Thi Thu Ha^{1*}, Nguyen Viet Quang¹, Ho Sy Hung^{1,2}, Vu Thi Diem Huong³

¹National Hospital of Obstetrics and Gynecology - 1 Trieu Quoc Dat Street, Hoan Kiem Dist, Hanoi City, Vietnam

²Hanoi Medical University - 1 Ton That Tung, Dong Da district, Hanoi City, Vietnam

³VNU, University of Medicine and Pharmacy - 144 Xuan Thuy, Cau Giay Dist, Hanoi City, Vietnam

Received: 03/06/2025

Revised: 15/06/2025; Accepted: 21/06/2025

ABSTRACT

Introduction: Outpatient hysteroscopy is an effective and safe diagnostic and therapeutic method for detecting intrauterine lesions in infertile women, especially in those with suggestive abnormalities or previous assisted reproductive failures.

Objectives: To evaluate the outcomes of outpatient hysteroscopy in infertile patients at the National Hospital of Obstetrics and Gynecology.

Methods: A descriptive study (combining retrospective and prospective data) was conducted on 149 infertile patients undergoing outpatient hysteroscopy at the National Center for Reproductive Assistance, National Hospital of Obstetrics and Gynecology, from November 2024 to April 2025.

Results: The mean age of the study population was 36.1 ± 5.2 years, with 64.4% of patients aged over 35. The median duration of infertility was 3 years (range: 1–28 years). Most patients had no prior intrauterine interventions (81.2%) and no history of uterine surgery (77.9%). Ultrasound detected intrauterine cavity abnormalities in 53.7% of cases (80/149), whereas hysterosalpingography (HSG) identified abnormalities in only 40% (14/35). The indication for diagnostic hysteroscopy is about 40.3%, including consecutive failed preimplantation (35.6%) and recurrent miscarriage (4.7%). Outpatient hysteroscopy confirmed intrauterine pathology in 81.2% of cases, predominantly endometrial polyps (46.3%), endometritis (16.1%), and intrauterine adhesions (18.1%). Interventions during hysteroscopy included polypectomy (46.3%), adhesiolysis of the uterine cavity (18.1%), submucosal myomectomy (1.3%), and endometrial biopsy (2.7%). The median procedure time was 8 minutes (range: 3–30 minutes), with no complications reported. The median volume of saline used was 800 ml (range: 60–3000 ml). Ultrasound showed strong agreement with hysteroscopy in diagnosing polyps (Kappa = 0.824; $p < 0.001$), whereas HSG demonstrated poor agreement in detecting both polyps and intrauterine adhesions (Kappa < 0.2; $p < 0.05$).

Conclusion: Office hysteroscopy is an effective tool for detecting intrauterine lesions in infertile patients. It allows both diagnosis and intervention in a short duration and is safe for the patient.

Keywords: Infertility; Outpatient hysteroscopy; Intrauterine abnormalities; Endometrial polyp; Intrauterine adhesions.

*Corresponding author

Email: dr.hanguyen.nhog@gmail.com **Phone:** (+84) 965995599 **Https://doi.org/10.52163/yhc.v66ienglish.2733**

1. INTRODUCTION

Infertility is a significant reproductive health issue, affecting approximately 15–17% of couples of reproductive age worldwide. According to the World Health Organization (WHO), infertility is defined as the failure to achieve a clinical pregnancy after at least 12 months of regular, unprotected sexual intercourse [1]. The causes of infertility are diverse, including male factors, ovulatory disorders, bilateral tubal occlusion, and uterine abnormalities. Among these, intrauterine abnormalities (such as endometrial polyps, intrauterine adhesions, submucosal fibroids, and uterine malformations) can directly affect embryo implantation and the maintenance of pregnancy, thereby leading to infertility or recurrent miscarriage [2].

Currently, there are various methods to evaluate the uterine cavity; however, most of these lack absolute accuracy and may miss small or flat lesions (such as small polyps or chronic endometritis), and sometimes produce false-positive results [3]. While transvaginal ultrasound and saline infusion sonohysterography have sensitivity and specificity rates of 82–90% and 56–60% respectively, hysteroscopy offers a sensitivity of 97% and specificity of 92% in diagnosing intrauterine abnormalities [4]. Therefore, hysteroscopy is considered the gold standard for direct assessment of the uterine cavity, enabling both diagnosis and simultaneous intervention when necessary [2]. Numerous studies have demonstrated the role of hysteroscopy in the diagnosis and treatment of infertility. The rate of detecting abnormalities through hysteroscopy in infertile women has been reported to vary widely, ranging from 19% to 62%, depending on the study population [4]. A study conducted in Nigeria reported that up to 70.4% of infertile patients had intrauterine lesions on hysteroscopy, with intrauterine adhesions accounting for 47.8%, polyps 17.6%, and submucosal fibroids 11.9% [2]. Meanwhile, other reports have indicated that endometrial polyps are the most common lesions in infertile women, accounting for approximately 10–32% of cases [5]. If these lesions are identified and managed promptly, the chances of conception may improve. Conversely, if overlooked, they may constitute hidden causes of infertility or recurrent implantation failure.

In Vietnam, outpatient hysteroscopy is increasingly applied in infertility evaluation due to its efficacy, convenience, and safety. However, domestic data on the effectiveness of this method, particularly in infertile patients, remain limited. Therefore, we conducted this study titled “Outcomes of Outpatient Hysteroscopy in Infertile Women at the National Hospital of Obstetrics and Gynecology”,

aimed at describing patient characteristics and detected lesions, thereby evaluating the role of hysteroscopy in diagnosing infertility.

2. MATERIALS AND METHODS

2.1. Participants

The study population comprised 149 infertile patients who underwent outpatient hysteroscopy at the National Center for Reproductive Assistance, National Hospital of Obstetrics and Gynecology, from November 2024 to April 2025.

2.1.1. Inclusion criteria

Women diagnosed with infertility according to WHO criteria (failure to achieve pregnancy after ≥ 12 months of regular unprotected intercourse) who had indications for hysteroscopy when at least one of the following factors was present: suspected intrauterine abnormalities on ultrasound or hysterosalpingography (HSG), history of recurrent miscarriage or stillbirth, ≥ 2 failed embryo transfer cycles in IVF, or multiple associated risk factors.

2.1.2. Exclusion criteria

Pregnancy, acute genital infections, contraindications to hysteroscopy, or refusal to participate in the study.

2.2. Study design

2.2.1. Study design:

A descriptive cross-sectional study combining retrospective and prospective data was conducted from November 2024 to April 2025.

2.2.2. Sample size and sampling method:

The sample size was calculated using the formula for estimating a proportion in a descriptive study, aiming to estimate a prevalence within the population.

$$n = Z_{1-\alpha/2}^2 \frac{p(1-p)}{d^2}$$

In which:

+ n is the required sample size.

+ p is the estimated proportion of intrauterine abnormalities detected by hysteroscopy in infertile patients, based on the study by Martin Koskas, with $p = 0.393$ [6].

+ d is the desired margin of error between the sample estimate and the population parameter (set at 20% of p).

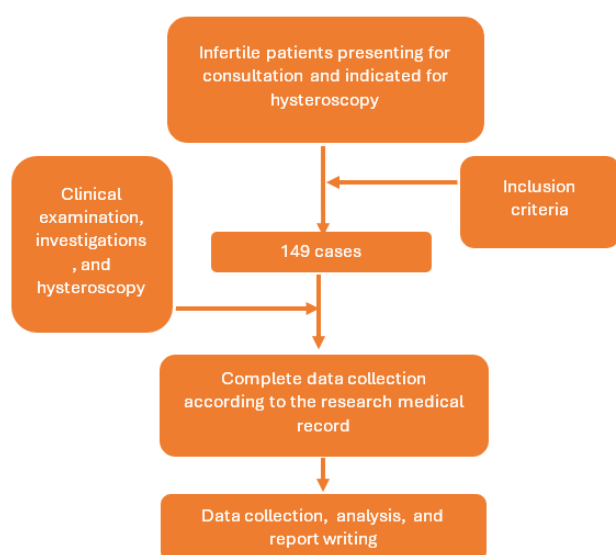
+ α is the significance level, set at 0.05, which corresponds to $Z_{1-\alpha/2} = 1.96$.

From this, the minimum required sample size was calculated as 148 patients. In reality, we collected data on 149 patients who met the inclusion criteria.

2.3. Statistical methods

Data were collected and analyzed using SPSS version 22.0. Quantitative variables were presented as mean \pm standard deviation (SD) or median (range), while qualitative variables were expressed as frequencies and percentages. Differences between groups were analyzed using the Chi-square test (for proportions) or Student's t-test (for means), with a significance level of $p < 0.05$. The agreement between diagnostic methods was assessed using the Kappa statistic.

2.4. Data collection process



2.5. Ethical considerations

The study was approved by the Board of Directors of the National Hospital of Obstetrics and Gynecology and complied with the ethical regulations for medical research as stipulated by the Ministry of Health. Patient information was kept confidential in accordance with regulations, and the study results were used solely for the purpose of understanding the current situation, improving, and enhancing diagnostic and treatment procedures to benefit reproductive healthcare services, without any other intended purpose.

3. RESULTS

During the study period, 149 infertile patients met the inclusion criteria.

Table 1. General characteristics of the study population

Characteristics (n=149)	
Age (years)	36.1 \pm 5.2
< 35	53 (3.6)
\geq 35	96 (64.4)
Type of infertility	
Primary infertility	56 (37.6)
Secondary infertility	93 (62.4)
Duration of infertility (years)	3 (1-28)
<5 years	116 (77.9)
\geq 5 years	33 (22.1)
History of intrauterine intervention	
No intervention	121 (81.2)
Curettage, uterine aspiration	19 (12.8)
Hysteroscopy	9 (6.0)
Cesarean section history	
No	116 (77.9)
Yes	33 (22.1)
History of assisted reproductive technology	
No	54 (36.2)
IUI	12 (8.1)
IVF	83 (55.7)

Value was given as mean \pm SD, number (%), or median (min–max)

Remarks: The majority of infertile patients were aged ≥ 35 years (64.4%) and had secondary infertility (62.4%). Infertility duration of <5 years was predominant (77.9%). Most patients had no history of intrauterine intervention (81.2%) and no history of uterine surgery (77.9%).

Table 2. Characteristics of transvaginal ultrasound and hysterosalpingography (HSG) findings in the study population

Ultrasound (n=149)		
Endometrium Thickness (mm)		8 (3-19)
Uterine cavity	Normal	69 (46.3)
	Endometrial polyp	68 (45.6)
	Submucosal uterine fibroid	1 (0.7)
	Intrauterine adhesion	9 (6.0)
	Endometrial hyperplasia	1 (0.7)
	Cesarean scar defect	1 (0.7)
Hysterosalpingography (HSG) (n=35)		
Uterine cavity	Normal	21 (6.0)
	Intrauterine adhesion	8 (22.9)
		6 (17.1)
Fallopian tubes	Normal	26 (74.2)
	Left fallopian tube occlusion	3 (8.6)
	Right fallopian tube occlusion	3 (8.6)
Bilateral fallopian tube occlusion		3 (8.6)
Positive Cotte's test		32 (91.4)

Value was given as median (min–max) and number (%)

Remarks: The median endometrial thickness was 8 mm (range: 3–19 mm). Ultrasound most frequently detected endometrial polyps (45.6%) as intrauterine abnormalities. HSG identified abnormalities in 40% of cases, including intrauterine adhesions in 22.9% and endometrial polyps in 17.1%.

Table 3. Indications for and findings of hysteroscopy in the study population

Indications for hysteroscopy (n=149)		
Diagnostic hysteroscopy		60 (40.3)
	≥2 failed embryo transfers	53 (35.5)
	Recurrent miscarriage or stillbirth	7 (4.7)

Indications for hysteroscopy (n=149)		
Operative hysteroscopy		89 (59.7)
	Endometrial polyp	74 (49.6)
	Intrauterine adhesion	14 (9.3)
	Endometrial hyperplasia	1 (0.7)
Hysteroscopy findings (n=149)		
Cervix	Normal	142 (95.3)
	Cervical stenosis	6 (4.0)
	Cervical polyp	1 (0.7)
Uterine cavity	Normal	28 (18.8)
	Endometrial polyp	69 (46.3)
	Submucosal uterine fibroid	3 (2.0)
	Intrauterine adhesion	27 (18.1)
	Endometrial hyperplasia	6 (4.0)
	Endometritis	24 (16.1)
	Cesarean scar defect	2 (1.3)
Fallopian tubes	Both tubal ostia visible	146 (98.0)
	Both tubal ostia not visible	3 (2.0)
Interventions performed during hysteroscopy	No intervention	50 (31.6)
	Polypectomy	69 (46.3)
	Myomectomy	2 (1.3)
	Adhesiolysis	27 (18.1)
	Endometrial biopsy	4 (2.7)
Procedure duration (minutes)		8 (3-30)
Volume of saline used (ml)		800 (60-3000)

Value were given as number(%), median (min–max)

Remarks: Diagnostic hysteroscopy accounted for 40.3% of cases, while operative hysteroscopy was performed in 59.7%. Hysteroscopy detected abnormalities in 81.2% of patients, mainly endometrial polyps (46.3%) and intrauterine adhesions (18.1%). Immediate intervention during the procedure was carried out in 68.9% of patients, most commonly polypectomy (46.3%). The median procedure time was 8 minutes (range: 3–30 minutes), and the median volume of saline used was 800 ml (range: 60–3000 ml).

Table 4. Comparison of the agreement between ultrasound, hysterosalpingography (HSG), and hysteroscopy findings

	Hysteroscopy					
	Endometrial polyp		Kappa index	Intrauterine adhesion		Kappa index
	No	Yes		No	Yes	
Ultrasound (n=149)	n=80	n=69	0.824 p=0.000	n=122	n=27	0.053 p=0.044
No	74 (49.7)	7 (4.7)		121 (81.2)	19 (12.8)	
Yes	6 (4.0)	62 (41.6)		1 (0.7)	8 (5.4)	
HSG (n=35)	n=28	n=7	0.053 p=0.044	n=22	n=13	0.126 p=0.001
No	25 (71.4)	4 (11.4)		21 (60.0)	6 (17.1)	
Yes	3 (8.6)	3 (8.6)		1 (2.9)	7 (20.0)	

Value were given as number(%) and Kappa test

Remarks: In the diagnosis of polyps, ultrasound showed a high level of agreement with hysteroscopy (Kappa = 0.824; $p < 0.001$). In contrast, HSG demonstrated low agreement with hysteroscopy in diagnosing both intrauterine adhesions and polyps (Kappa < 0.2; $p < 0.05$); there were 6 patients with normal HSG results who were found to have intrauterine adhesions on hysteroscopy.

4. DISCUSSION

The group of infertile women in this study had a relatively high mean age (36.1 ± 5.2 years; 64.4% aged ≥ 35 years) and predominantly secondary infertility (62.4%) (Table 1). This is consistent with the notion that the risk of intrauterine abnormalities increases with age [7]. The duration of infertility was generally short (<5 years in 77.9%), and many patients had undergone in vitro fertilization (IVF) (55.7%) prior to hysteroscopy. Most patients had no history of intrauterine intervention or cesarean section, suggesting that the newly detected lesions on hysteroscopy could be the underlying cause of infertility.

Ultrasound suspected endometrial polyps in nearly 46% of cases and intrauterine adhesions in 6% (Table 2). These figures closely match the hysteroscopic findings, indicating that ultrasound is an effective initial screening tool. Conversely, hysterosalpingography (HSG) in a smaller sample (35 cases) showed 60% normal findings, 22.9% intrauterine adhesions, and 17.1% polyps. As reported by Dalfó et al. (2004), HSG has a sensitivity of 81% and specificity of 80% compared to

hysteroscopy [8], suggesting that while it remains a useful screening method, it cannot fully replace hysteroscopy [9].

Table 3 shows that indications for hysteroscopy included diagnostic purposes (40.3%) and operative purposes (59.7%), with polypectomy being the most common intervention (49.6%), reflecting the very high frequency of endometrial polyps (46.3%). This rate far exceeds those reported in previous studies of the general infertile population (typically around 10–15%) and is higher than domestic reports [7]. The overall rate of intrauterine abnormalities detected by hysteroscopy was 81.2%, with endometrial polyps being the most common (46.3%), followed by adhesions (18.1%), endometritis (16.1%), submucosal fibroids (2.0%), and cesarean scar defects (1.3%). This rate is significantly higher than in both national and international studies: Ngoc et al. (Tam Anh General Hospital) reported abnormalities in 55.1% of patients with recurrent implantation failure (RIF), with endometritis being the most common (29.6%) [3]; Salazar-Jiménez et al. (Mexico) found abnormalities in 61.8% of infertile women (polyps 26.7%, endometritis 15.7%, fibroids 7.6%, and adhesions 6.5%) [4]; and Ugboaja et al. (Nigeria) reported abnormalities in 70.4% (adhesions 47.8% and polyps 17.6%) [2]. This difference is primarily due to the fact that our patient group had been preselected based on clinical or imaging suspicion, resulting in a higher positive rate. These findings support the view that hysteroscopy should be performed early in infertile women at high risk (e.g., older age, IVF failure) to detect potential lesions.

The interventional outcomes were also noteworthy: 68.9% of patients received treatment during hysteroscopy (46.3% polypectomy, 18.1% adhesiolysis), demonstrating that outpatient hysteroscopy allows for both diagnosis and definitive treatment in a single session. The procedure was of short duration (median 8 minutes) and no complications occurred, confirming its safety—consistent with the findings of Vu Thi Ngoc (2023), who also reported no complications [3].

The analysis of diagnostic agreement showed a high concordance between ultrasound and hysteroscopy in detecting polyps (Kappa = 0.824; $p < 0.001$) (Table 4). This indicates that ultrasound is a good tool for predicting positive polyp findings. Meanwhile, HSG showed poor agreement with hysteroscopy for both polyps and adhesions (Kappa < 0.2 ; $p < 0.05$). Six patients had normal HSG results but were found to have adhesions on hysteroscopy; these missed cases on HSG typically involved minimal or thin adhesions. These findings are consistent with the report by Dalfó (2004) on the supplementary role of HSG in initial screening. However, to confirm the diagnosis and ensure timely treatment, hysteroscopy—with its direct visualization capability—remains the gold standard [8].

5. CONCLUSIONS

Outpatient hysteroscopy is a safe, minimally painful, and effective diagnostic method for detecting intrauterine abnormalities in infertile women with indications. With its high detection rate and ability to provide immediate treatment, this technique should be integrated into the infertility evaluation protocols at reproductive assistance centers, particularly for patients with suggestive clinical signs or imaging findings.

REFERENCES

- [1] Infertility Prevalence Estimates, 1990-2021, World Health Organization, Geneva. 2023.
- [2] Ugboaja J.O., Oguejiofor C.B., Igwegbe A.O. et al. Abnormal Hysteroscopy Findings among a Cross Section of Infertile Nigerian Women. *Niger J Clin Pract.* 2019, 22(1), 9.
- [3] Ngoc V.T., Do L.Q., Thuy N.M. and cs. Outpatient hysteroscopy findings in patients with recurrent implantation failure at Tam Anh General Hospital. *Vietnam Medical Journal*, 2023. 524(2).
- [4] Salazar-Jiménez C., Crespo-Zhindón E.F., Pedraza-González L.A. et al. Hysteroscopic findings and intrauterine pathology treatment in Mexican infertile women. *Int J Reprod Contracept Obstet Gynecol*, 2023. 12(8), 2321–2326.
- [5] Penzias A., Azziz R., Bendikson K. et al. Fertility evaluation of infertile women: a committee opinion. *Fertil Steril*, 2021, 116(5), 1255–1265.
- [6] Koskas M., Mergui J.-L., Yazbeck C. et al. Office Hysteroscopy for Infertility: A Series of 557 Consecutive Cases. *Obstet Gynecol Int*, 2010, 168096.
- [7] Abdel Aal H.M.H., El- Shahat E.-M.F., và Beltagy M.A.M.M. Role of Hysteroscopy in Diagnosis of Patients with Secondary Infertility. *Al-Azhar Int Med J*, 2024, 5(6).
- [8] Roma Dalfó A., Úbeda B., Úbeda A. et al. Diagnostic Value of Hysterosalpingography in the Detection of Intrauterine Abnormalities: A Comparison with Hysteroscopy. *Am J Roentgenol*, 2004, 183(5), 1405–1409.
- [9] Hou J.-H., Lu B.-J., Huang Y.-L. et al. Outpatient hysteroscopy impact on subsequent assisted reproductive technology: a systematic review and meta-analysis in patients with normal transvaginal sonography or hysterosalpingography images. *Reprod Biol Endocrinol*, 2024. 22(1), 18.